

# Using Functional Magnetic Resonance Imaging to Detect Covert Awareness in the Vegetative State

Adrian M. Owen, PhD; Martin R. Coleman, PhD; Melanie Boly, PhD; Matthew H. Davis, PhD; Steven Laureys, MD, PhD; John D. Pickard, MD, PhD

**T**he assessment of patients with disorders of consciousness, including the vegetative state, is difficult and depends frequently on subjective interpretations of the observed spontaneous and volitional behavior. For those patients who retain peripheral motor function, rigorous behavioral assessment supported by structural imaging and electrophysiological findings is usually sufficient to establish a patient's level of wakefulness and awareness. However, it is becoming increasingly apparent that in some patients damage to the peripheral motor system may prevent overt responses to command although the cognitive ability to perceive and understand such commands may remain intact. Recent advances in functional neuroimaging suggest a novel solution to this problem; in several cases, so-called activation studies have been used to identify residual cognitive function and conscious awareness in patients who are assumed to be in a vegetative state yet retain cognitive abilities that have evaded detection using standard clinical methods.

*Arch Neurol.* 2007;64(8):1098-1102

The vegetative state is one of the least understood and most ethically troublesome conditions in modern medicine. *Vegetative state* describes a unique disorder in which patients who emerge from coma appear to be awake but show no signs of awareness of self or of environment. At the point that the diagnosis is made there must be no evidence of sustained, reproducible, purposeful, or voluntary behavioral response to visual, auditory, tactile, or noxious stimuli. There must also be no evidence of language comprehension or expression, although there are generally sufficiently preserved hypothalamic and brainstem autonomic functions to permit survival with medical care.

An accurate and reliable evaluation of the level and content of cognitive processing is of paramount importance for the appropriate management of patients diagnosed as being in a vegetative state.

Objective behavioral assessment of residual cognitive function can be difficult in these patients due to the fact that motor responses (the only means of communicating awareness in the absence of speech) may be minimal, inconsistent, and difficult to document or may be undetectable because no cognitive output is possible. Several recent studies reviewed by Laureys et al<sup>1</sup> have shown that functional neuroimaging may have an important role in the identification of residual cognitive function in some patients who are assumed to be in a vegetative state yet retain cognitive abilities that have evaded detection using standard clinical approaches. Unlike resting blood flow and glucose metabolism, which provide markers of neural capacity and potential so-called activation methods such as radioactive water positron emission tomography and functional magnetic resonance (fMR) imaging can be used to link residual neural activity to the presence of covert cognitive function. In short, activation studies have the potential to demonstrate distinct and specific physiological responses (changes in regional cerebral blood flow or regional ce-

**Author Affiliations:** Medical Research Council Cognition and Brain Sciences Unit (Drs Owen and Davis) and Impaired Consciousness Study Group, Wolfson Brain Imaging Centre, University of Cambridge (Drs Coleman and Pickard), Cambridge, England; and Cyclotron Research Centre and Neurology Department, University of Liège, Liège, Belgium (Drs Boly and Laureys).

rebral hemodynamics) to controlled external stimulation without the need for any overt behavior (eg, a motor action) by the patient. Indeed, in recent years normal or near-normal patterns of brain activity have been reported in response to many types of stimuli, including faces, speech, and semantically ambiguous sentences in patients meeting all of the clinical criteria for a diagnosis of vegetative state.<sup>1</sup>

A question that is often asked of such studies is whether the presence of normal brain activation in patients who are diagnosed as being in a vegetative state indicates a level of conscious awareness, perhaps even similar to that which exists in healthy volunteers when performing the same tasks. Many types of stimuli, including faces, speech, and pain, will elicit automatic responses from the brain; that is to say, they will occur without the need for willful intervention on the part of the participant (eg, you cannot choose to not recognize a face or to not understand speech that is presented clearly in your native language). By the same argument, normal neural responses in patients who are diagnosed as being in a vegetative state do not necessarily indicate that these patients have any conscious experience associated with processing those same types of stimuli. Therefore, such patients may retain discreet islands of subconscious cognitive function that exist in the absence of awareness.

This logic exposes a central conundrum in the study of conscious awareness and particularly in how it relates to the vegetative state. Deeper philosophical considerations notwithstanding, the only reliable method that we have for determining if another being is consciously aware is to ask him or her. The answer may take the form of a spoken response or a nonverbal signal (which may be as simple as the movement of a hand or a blink of an eye as documented cases of the locked-in syndrome have demonstrated), but it is this answer that allows us to infer conscious awareness. In short, our ability to know unequivocally that another being is consciously aware is ultimately determined not by whether or not he or she is aware but instead by his or

her ability to communicate that fact through a recognized behavioral response. But what if the ability to blink an eye or move a hand is lost yet conscious awareness remains? By definition, patients who are diagnosed as being in a vegetative state are unable to elicit such behavioral responses. Following the logic of this argument, even if such a patient were consciously aware, by definition he or she would have no means for conveying that information to the outside world.

## METHODS

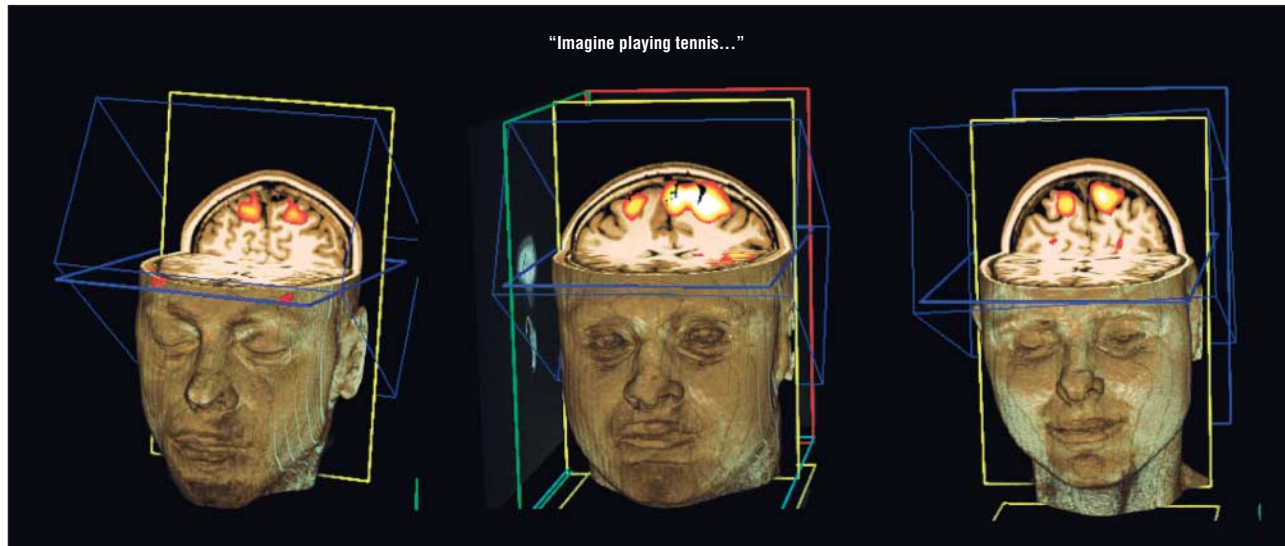
We recently described a novel approach to this conundrum, using fMR imaging to demonstrate preserved conscious awareness in a patient fulfilling the criteria for a diagnosis of being in a vegetative state.<sup>2</sup> In mid 2005, the patient was involved in a motor vehicle crash. On admission to the hospital, she had a Glasgow Coma Scale score of 4. A computed tomographic image revealed diffuse brain swelling, intraventricular blood in the left lateral ventricle, low attenuation in the left frontal lobe close to the corpus callosum, and attenuation change in the right frontal and left posterior temporal regions. The following day she underwent bifrontal decompressive craniectomy, and 1 month later a ventriculoperitoneal shunt was inserted into the right lateral ventricle. Between the time of the crash and the fMR imaging in early January 2006, the patient was assessed by a multidisciplinary team using repeated standardized assessments consistent with the procedure described by Bates.<sup>3</sup> Throughout this period, the patient's behavior was consistent with accepted guidelines defining the vegetative state.<sup>4</sup> She opened her eyes spontaneously, exhibited sleep-wake cycles, and had preserved but inconsistent reflexive behavior (startle, noxious, threat, tactile, and olfactory). No elaborated motor behaviors (regarded as voluntary or willed responses) were observed from the upper or lower limbs. There was no evidence of orientation, fixation greater than 5 seconds, or tracking to visual or auditory stimuli. No overt motor responses to command were observed.

Before the fMR imaging, the patient was instructed to perform 2 mental imagery tasks when cued by the instructions "imagine playing tennis" or "imagine visiting the rooms in your home." These instructions were elaborated outside of the scanner in an attempt to in-

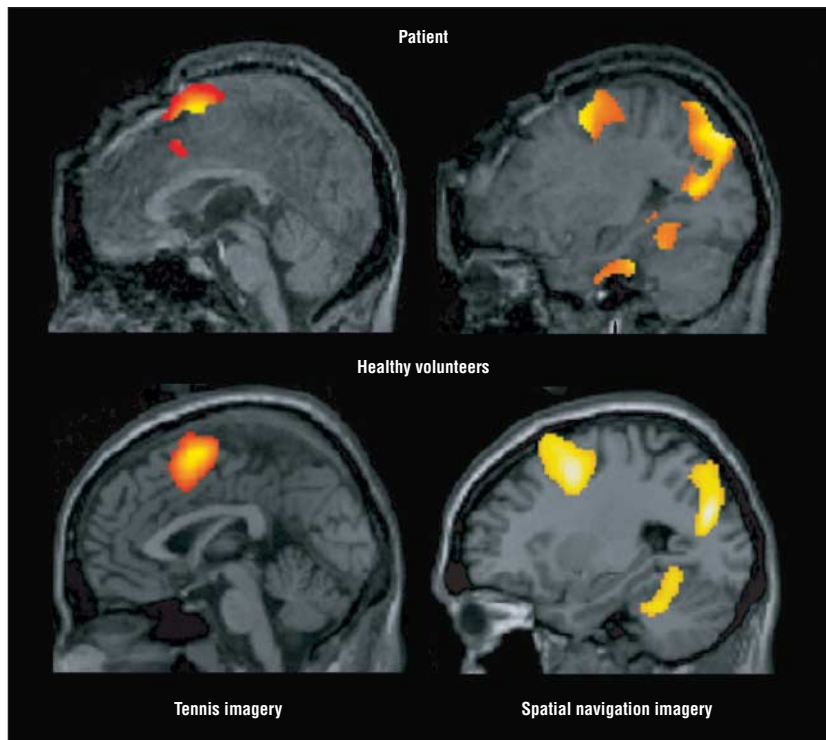
duce a rich and detailed mental picture during the imaging. Therefore, one task involved imagining playing a vigorous game of tennis, swinging for the ball with forehand and backhand, for the entire duration of each imaging block. The other task involved imagining moving slowly from room to room in her house, visualizing the location and appearance of each item of furniture as she did so. In a third condition, the patient was asked to "just relax."

Most important, these particular tasks were chosen not because they involve a set of fundamental cognitive processes that are known to reflect conscious awareness but because imagining playing tennis and imagining moving around the house elicit reliable, robust, and statistically distinguishable patterns of activation in specific regions of the brain. For example, in a series of studies<sup>2,5</sup> in healthy volunteers, imagining playing tennis has been shown to elicit activity in the supplementary motor area, a region involved in imagining (as well as actually performing) coordinated movements in 34 participants imaged (**Figure 1**). In contrast, imagining moving from room to room in a house commonly activates the parahippocampal cortices, the posterior parietal lobe, and the lateral premotor cortices, regions that contribute to imaginary or real spatial navigation. Given the reliability of these responses across individuals, activation in these regions can be used as a neural marker, confirming that the participant retains the ability to understand instructions, carry out different mental tasks in response to those instructions, and exhibit willed voluntary behavior in the absence of any overt action.

When the patient who was clinically diagnosed as being in a vegetative state was asked to imagine playing tennis, significant activity was observed in the supplementary motor area that was statistically indistinguishable from that observed in healthy awake volunteers (**Figure 2**).<sup>2</sup> In contrast, the instruction to imagine walking through the rooms of her house elicited significant activity in the parahippocampal gyrus, posterior parietal cortex, and lateral premotor cortex, which was again indistinguishable from that observed in healthy volunteers. Despite her fulfilling all of the clinical criteria for a diagnosis of being in a vegetative state, we concluded that this patient retained the ability to understand spoken commands and to respond to them through her brain activity rather than through speech or movement. Moreover, her decision to cooperate with us by imagining particular tasks when asked to do so repre-



**Figure 1.** Three healthy volunteers imagine playing tennis during real-time functional magnetic resonance (MR) imaging at the Medical Research Council Cognition and Brain Sciences Unit, Cambridge, England. Functional MR imaging data are superimposed on 3-dimensional anatomical reconstructions of structural MR data for online examination of brain activity during the imaging period. Similar significant activation is observed in the supplementary motor area in all 3 volunteers.



**Figure 2.** Supplementary motor area activity during tennis imagery in a patient diagnosed as being in a vegetative state and in a healthy volunteer (left). Parahippocampal gyrus, posterior parietal lobe, and lateral premotor cortex activity while imagining moving around a house in the patient and in a healthy volunteer (right).

sented a clear act of intention that confirmed beyond any doubt that she was consciously aware of herself and her surroundings.

Skeptics may argue that the words *tennis* and *house* could have automatically triggered the patterns of activation observed in the supplementary motor area, parahippocampal gyrus, posterior parietal lobe, and lateral pre-

motor cortex in our patient in the absence of conscious awareness. However, we know of no data supporting the inference that such stimuli can unconsciously elicit sustained hemodynamic responses in these regions of the brain. Indeed, considerable data exist to suggest that such words do not elicit the responses that were observed. For example, although it is well documented

that some words can under certain circumstances elicit wholly automatic neural responses in the absence of conscious awareness, such responses are typically transient (ie, lasting for a few seconds) and, not surprising, occur in regions of the brain that are associated with word processing.<sup>6</sup> In our patient, the observed activity was not transient but persisted for the full 30 seconds of each imagery task (ie, far longer than would be expected given the hemodynamics of the fMR imaging response). In fact, these task-specific changes persisted until the patient was cued with another stimulus indicating that she should rest. Such responses are impossible to explain in terms of automatic brain processes. In addition, the activation observed in the patient was not in brain regions that are known to be involved in word processing, but rather was in regions that are known to be involved in the 2 imagery tasks that she was asked to carry out. Again, sustained activity in these regions of the brain is impossible to explain in terms of unconscious responses to single keywords or to short sentences containing those words. In fact, we recently demonstrated that non-instructive sentences containing the same keywords as those used with our patient (eg, “the man enjoyed playing tennis”) produce no sustained activity in any of these brain regions in healthy volunteers.<sup>7</sup> Therefore, the most parsimonious explanation is that this patient was consciously aware and was willfully following the instructions given to her, despite her diagnosis of being in a vegetative state.



## RELEVANCE TO THE PRACTICE OF NEUROLOGY

This finding raises several important issues regarding the use of functional neuroimaging in the assessment of patients with disorders of consciousness. First, although this technique provides a new means for detecting conscious awareness when standard clinical approaches are unable to provide that information, the method will not be applicable to all patients in a vegetative state. For example, within 6 months of traumatic brain injury (as was the case for the patient described herein), the incidence of recovery of consciousness following traumatic brain injury remains at almost 20%, with a quarter of those recovering moving on to an independent level of function.<sup>8</sup> Nontraumatic injuries are considered to have a much poorer prognosis. Similarly, the likelihood of recovery is much lower in patients who meet the diagnostic criteria for being in a permanent vegetative state (the patient described herein did not). International guidelines, including those of the Royal College of Physicians in England and the Multi-Society Task Force representing 5 major medical societies in the United States, suggest that a diagnosis of being in a permanent vegetative state should not be made until 12 months after injury in cases of traumatic brain injury or until 6 months after injury in cases of anoxic brain injury.<sup>8</sup> In many of these cases, standard clinical techniques, including structural MR imaging, may be sufficient to rule out any potential for normal activation, without the need for fMR imaging.

That said, although it is almost certainly the case that similar fMR imaging responses will not be found in most patients who meet the clinical criteria for being in a vegetative state, there is little a priori reason to suppose that this is the only patient for whom this will be the case. In fact, we recently assessed a second patient with traumatic brain injury who showed evidence of eye opening, sleep-wake cycles, and preserved reflexes but no sustained, reproducible, or purposeful overt behavioral response to sensory or cognitive stimulation. How-

ever, he exhibited consistent patterns of brain activity when asked to imagine playing a game of soccer. This activity was observed in medial and lateral regions of the supplementary motor cortex, consistent with actual or imagined movement of the legs and lower body.

It is important to emphasize that negative functional neuroimaging findings in patients who are diagnosed as being in a vegetative state cannot be used as evidence for lack of awareness. For example, a patient may fall asleep during the imaging or may not have properly heard or understood the task instructions, leading to so-called false-negative results. Nevertheless, positive findings, when they occur and can be verified by careful statistical comparison with data from healthy volunteers, can be used to detect conscious awareness in patients without the need for conventional methods of communication such as movement or speech. On this basis, we suggest that functional neuroimaging should be more widely used in the assessment of patients with disorders of consciousness and particularly in those for whom existing clinical approaches have left some ambiguity about the diagnosis.

## RELEVANCE TO THE STUDY OF NEUROSCIENCE

In the past 2 decades, rapid technological developments in the field of neuroimaging have produced a cornucopia of new techniques for examining the structure and function of the human brain in vivo. Detailed anatomical images, acquired through computed tomography and MR imaging, can now be combined with positron emission tomography, fMR imaging, quantitative electroencephalography, and magnetoencephalography to produce a cohesive picture of normal and abnormal brain function. As a result, functional neuroimaging has become the technique of choice for neuropsychologists, cognitive neuroscientists, and many others in the wider neuroscientific community with an interest in the relationship between brain and behavior. Until recently, these new methods of in-

vestigation have been used primarily as a correlational tool to map the cerebral changes that are associated with a particular cognitive process or function, be it an action, a thought, or a reaction (eg, to some kind of external stimulation). However, recent advances in imaging technology and particularly in the ability of fMR imaging to detect reliable neural responses in individual participants in real time are beginning to allow reverse inferences to be made (ie, to correctly identify a participant's thoughts, actions, or intentions based solely on the pattern of activity that is observed in his or her brain). The case of the patient described herein provides an example of such an application. The fact that she was consciously aware was evident only by examination of her time-locked and sustained fMR imaging responses following instructions to perform specific mental tasks in the absence of any overt action. On this basis, it was possible to infer not only that she was thinking but also what she was thinking at any given point in time (within the constraints of the tasks given to her). Similarly, in another study,<sup>5</sup> healthy volunteers were instructed to choose to imagine playing tennis or navigating around their homes without informing the investigators of their choice. It was possible to determine with 100% accuracy which task was being performed by each participant during the imaging session based solely on his or her brain activity. Finally, in another recent fMR imaging study,<sup>9</sup> participants were asked to freely decide which of 2 different tasks to perform and to covertly maintain that intention during a variable delay. During the delay, it was possible to decode from activity in the prefrontal cortex which of the 2 tasks the participants were covertly intending to perform.

Such feats of rudimentary mind reading using fMR imaging pave the way for new and innovative applications of functional neuroimaging in basic neuroscience and in clinical practice. For example, the presence of reproducible and robust task-dependent fMR imaging responses to command without the need for any practice or training<sup>2</sup> suggests a

novel method by which healthy participants and patients may be able to communicate their thoughts to those around them by simply modulating their neural activity. The use of functional neuroimaging in this context will continue to present innumerable logistic and theoretical problems. However, its clinical and scientific implications are so great that such efforts are clearly justified.

**Accepted for Publication:** March 5, 2007.

**Correspondence:** Adrian M. Owen, PhD, MRC Cognition and Brain Sciences Unit, 15 Chaucer Rd, Cambridge CB2 7EF, England (adrian.owen@mrc-cbu.cam.ac.uk).

**Author Contributions:** *Study concept and design:* Owen, Coleman, Boly, Davis, Laureys, and Pickard. *Acquisition of data:* Owen and Coleman. *Analysis and interpretation of data:* Owen, Coleman, Boly, Davis, and Laureys. *Drafting of the manuscript:*

Owen, Coleman, and Davis. *Critical revision of the manuscript for important intellectual content:* Owen, Coleman, Boly, Davis, Laureys, and Pickard. *Statistical analysis:* Owen, Coleman, Boly, and Davis. *Obtained funding:* Owen and Pickard. *Administrative, technical, and material support:* Owen, Coleman, and Davis. *Study supervision:* Owen, Coleman, Laureys, and Pickard.

**Financial Disclosure:** None reported.

**Funding/Support:** This study was supported in part by program grant G9439390 ID 56833 to the Medical Research Council, The Smiths Charity, the Belgian "Fonds National de la Recherche Scientifique," and the Mind Science Foundation.

## REFERENCES

1. Laureys S, Owen AM, Schiff N. Brain function in coma, vegetative state, and related disorders. *Lancet Neurol*. 2004;3(9):537-546.
2. Owen AM, Coleman MR, Davis MH, Boly M, Laureys S, Pickard JD. Detecting awareness in the vegetative state. *Science*. 2006;313(5792):1402.
3. Bates D. The vegetative state and the Royal College of Physicians guidance. *Neuropsychol Rehabil*. 2005;15(3-4):175-183.
4. Royal College of Physicians. The vegetative state: guidance on diagnosis and management. In: *Report of a Working Party*. London, England: Royal College of Physicians; 2003.
5. Boly M, Coleman MR, Davis MH, et al. When thoughts become action: an fMRI paradigm to study volitional brain activity in non-communicative brain injured patients [published online ahead of print March 13, 2007]. *Neuroimage*. doi:10.1016/j.neuroimage.2007.02.47.
6. Hauk O, Johnsrude I, Pulvermuller F. Somatotopic representation of action words in human motor and premotor cortex. *Neuron*. 2004;41(2):301-307.
7. Owen AM, Coleman MR, Davis MH, Boly M, Laureys S, Pickard JD. Response to comments on "Detecting awareness in the vegetative state" [technical comment]. *Science*. 2007;315(5816):1221. doi:10.1126/science.1135583.
8. Jennett B. *The Vegetative State: Medical Facts, Ethical and Legal Dilemmas*. New York, NY: CUP; 2002.
9. Haynes JD, Sakai K, Rees G, Gilbert S, Frith C, Passingham RE. Reading hidden intentions in the human brain [published online ahead of print February 8, 2007]. *Curr Biol*. 2007;17(4):323-328. doi:10.1016/j.cub.2006.11.072.

## Announcement

**Topic Collections.** Archives offers collections of articles in specific topic areas to make it easier for physicians to find the most recent publications in a field. These are available by subspecialty, study type, disease, or problem. In addition, you can sign up to receive a Collection E-Mail Alert when new articles on specific topics are published. Go to <http://archneur.ama-assn.org/collections> to see these collections of articles.